GENETIC THERAPY, INC.

A Novartis Company

# ATTENUATION OF HEPATIC FIBROSIS OBSERVED WITH A "GUTLESS" ADENOVIRAL VECTOR

L M King[1], J E Markovits[2], C A Mech[1], L E Dinges[1], J Zhao[1] and R M Lyons[1]

[1]Genetic Therapy, Inc., Gaithersburg, MD, USA; [2]Novartis Pharmaceuticals, East Hanover, NJ, USA

## ABSTRACT:

Adenoviral vectors are being explored as potential therapeutic agents, although clinical utility has been limited due to the adverse effects seen in liver following intravenous injection. In previous studies, we demonstrated in male monkeys and CD-1 mice that an early generation adenoviral vector caused hepatocellular apoptosis and activation of hepatic stellate cells with subsequent fibrosis. In this study, in order to determine if viral gene expression contributes to hepatic toxicity, male and female CD-1 mice were injected with $5 \times 10^{11}$ (low dose), $3 \times 10^{12}$ (mid dose) or $1.5 \times 10^{13}$ (high dose) viral particles/kg of either an early generation vector (Av3Null) or a "gutless" vector with all viral genes removed (AGVNull). Serum IL-6 levels were measured during the first week after dosing. Selected clinical pathology parameters were evaluated on days 2, 8, 15, 29, 43 and 57. Histopathology was evaluated at day 57. Dramatic increases (~200 fold) in serum IL-6 levels were seen in high dose mice 6 hours after receiving either vector. Significant elevations in serum liver enzymes were seen in high dose mice with either vector on day 2, with a decrease in platelets observed in these animals at day 4. Values returned to normal by the termination of the study. Morphological changes were present following treatment with either vector and included hepatocellular apoptosis, extramedullary hematopoiesis, activation of stellate cells and increased extracellular matrix production. Hepatic fibrosis (as measured by sirius red index) in both sexes was not significantly different from controls following treatment with the gutless vector, but significant differences were seen in Av3Null-treated animals. In summary, liver changes produced by the gutless vector were less severe than those due to Av3Null. Since serum liver enzyme measurements did not reveal these vector-induced hepatic changes, studies are currently underway to determine if serum collagen and alpha-GST levels can be used as markers for early detection of hepatic injury and fibrosis.

## MATERIALS and METHODS:

***Vectors:*** Av3Null, contains the Av3 viral backbone
AGVNul, the "gutless" vector, with all viral genes removed

***Study Design:***
Male and female CD-1 mice (n = 10/sex/group) were injected intravenously with:

- **HBSS**
- **Av3Null** vector at 3 doses: Lo ($6.0 \times 10^{11}$ vp/kg), or Mid ($3.0 \times 10^{12}$ vp/kg)
- **AGVNull** vector at 1 dose: Hi ($1.5 \times 10^{13}$ vp/kg)

***Assessments:***

- Tissue morphology by H&E
- Laminin and smooth muscle specific actin immunoreactivity
- Fibrosis by semiquantitative and morphometric evaluation of sirius red stained tissue sections
- Hematology: WBC, RBC, PLT, DIFF
- Clinical chemistry: AST, ALT, ALP, TBIL
- Cytokines: IL-6 (BioSource International mouse IL-6 immunoassay)

Hematology, clinical chemistry and cytokine data from male and female animals were combined within groups because no sex-related differences were observed. Fibrosis data and histopathology findings from male and female animals were combined for purposes of presentation. Overall, some sex-related differences were observed, with a lower incidence of most lesions in females.

***For analysis of:***

- Serum α-GST (Biotrin rat α-GST immunoassay)
- Serum collagen (Biotrin rat serum collagen immunoassay)

Male CD-1 mice (n = 3/group/timepoint) were injected intravenously with:

- **HBSS**
- **Av3Null** vector at $15 \times 10^{13}$ vp/kg (Hi dose)

## ABBREVIATIONS:

| | |
|---|---|
| ALP | Alkaline Phosphatase |
| ALT | Alanine aminotransferase |
| AST | Aspartate transaminase |
| α-GST | Alpha glutathione-S-Transferase |
| DIFF | Differential leukocyte count |
| HBSS | Hanks Balanced Salt Solution |
| PLT | Platelet count |
| RBC | Erythrocyte count |
| TBIL | Total Bilirubin |
| WBC | Total leukocyte count |

**Figure 1: Liver, HBSS treated, SD57**

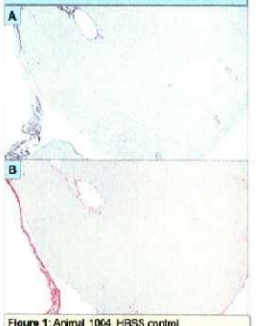


**Figure 1:** Animal 1004, HBSS control
Original magnification 100X
A = Laminin immunoreactivity,
B = Sirius red stain

**Figure 2: Liver, Av3Null treated, SD57**

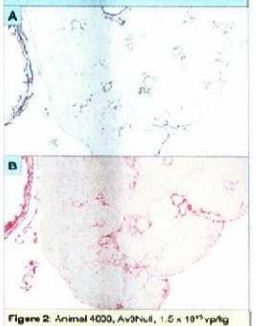


**Figure 2:** Animal 4000, Av3Null, $1.5 \times 10^{13}$ vp/kg
Original magnification 100X
A = Laminin immunoreactivity
B = Sirius red stain

**Figure 3: Liver, AGVNull treated, SD57**




**Figure 3:** Animal 7503, AGVNull, $1.5 \times 10^{13}$ vp/kg
Original magnification 100X
A = Laminin immunoreactivity
B = Sirius red stain
* indicates mononuclear cell infiltrate

**TABLE 1.** Salient microscopic liver changes on SD57

| Vector Dose (particles/kg) | Control | Av3Null $1.5 \times 10^{13}$ | AGVnull $1.5 \times 10^{13}$ |
|---|---|---|---|
| Apoptosis | 2/20 | 17/20 | 11/20 |
| Karyomegaly | 0/20 | 15/20 | 3/20 |
| Cytomegaly | 0/20 | 4/20 | 0/20 |
| Intranuclear inclusion invaginated cytoplasm | 0/20 | 13/20 | 4/20 |
| Prominent sinusoidal lining cells | 0/20 | 8/20 | 1/20 |
| Extramedullary granulopoiesis | 1/20 | 6/20 | 1/20 |
| Mononuclear infiltrate | 4/20 | 19/20 | 19/20 |
| Pigment | 0/20 | 18/20 | 3/20 |
| Fibrosis | 4/20 | 19/20 | 7/20 |
| ↑ actin immunoreactivity | 1/20 | 13/20 | 4/20 |
| ↑ laminin immunoreactivity | 2/20 | 15/20 | 18/20 |

Data from males and females were combined, n = 20/group

**Figure 4: Sirius Red Index, SD57**

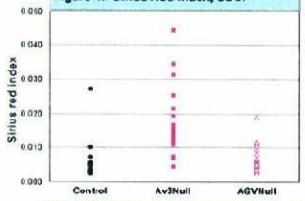


Hepatic tissue slides were assessed as described in Lab Invest 80:143-50, 2000 with modifications. Briefly, five representative fields per slide were digitized and image analysis was based on recognition of magenta staining. Results were based on the % of magenta staining observed, and expressed as the sirius red index. Slides were randomized and analysis was blinded to remove bias. Data from males and females was combined, n = 20/group.

*The authors would like to acknowledge the technical expertise of Gregory Argenieri for the morphometric analysis presented here.*

**Figure 5. Av3Null Histopathology, SD57**

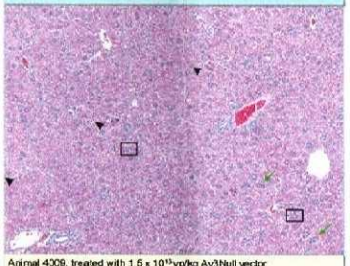

Animal 4009, treated with $1.5 \times 10^{13}$ vp/kg Av3Null vector
H&E staining, 100X
Apoptosis is indicated by ▼
Karyomegaly is indicated by ↗
Nuclear inclusions (invaginations of cytoplasm) are identified by □

**Figure 6: Clinical Chemistry**

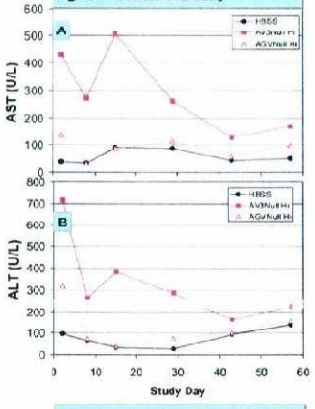


## RESULTS:

**Morphologic Assessment:** The salient morphological changes are summarized in Table 1, and shown in Fig 1-3 and 5. The most common changes of apoptosis, karyomegaly and invaginated cytoplasm/intranuclear inclusions are depicted in Fig 5.

**Laminin immunoreactivity:** Increased extracellular matrix demonstrated by laminin immunoreactivity was more severe in Av3Null-treated animals (Fig 2A) than those treated with AGVNull (Fig 3A). Control is shown in Fig 1A.

**Fibrosis:** Fibrosis, demonstrated by sirius red staining, was more severe in animals treated with Av3Null (Fig 2B) than AGVNull-treated animals (Fig 3B). Control is shown in Fig 1A. The sirius red index values are shown in Fig 4.

**Clinical Chemistry:** Levels for ALT and AST are shown in Fig 6A and B. Levels for ALP and T BIL were not significantly different between groups (data not shown). ALT and AST levels in AGVNull-treated animals were not significantly different from control animals. Animals treated with Av3Null showed significant elevations in ALT and AST from 2-15 days after treatment, with levels returning to controls by SD43.

**Hematology:** Levels for Platelets are shown in Fig 9. Lymphocyte levels were not significantly different between groups (data not shown), but platelet levels in both Av3Null- and AGVNull-treated animals were significantly lower at SD4, with levels returning to control by SD8.

**Serum α-GST:** Levels are shown in Fig 7. Serum α-GST began to rise in Av3Null-treated animals by SD8, with significant and sustained elevations observed by SD22 until the end of the study (SD57).

**IL-6:** Levels are shown in Fig 8. At 6 hrs after receiving vector, dramatic increases (~200 fold) were seen in animals treated with high dose. IL-6 levels in all groups returned to controls by 24 hrs.

**Serum Collagen:** Mouse serum collagen did not cross-react with the rat antibodies supplied in the assay. Data is not shown.

**Figure 7: Serum α-GST**

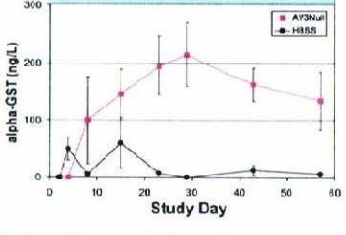


**Figure 8: IL-6 Levels**

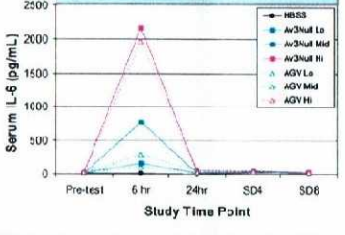


**Figure 9: Hematology**

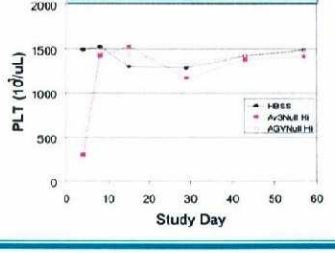


## CONCLUSIONS:

The earliest events following exposure to either the Av3Null or the AGVNull vector were the same, and were probably associated with the vector capsid. These changes included elevated IL-6 levels and decreased platelet counts.

In this study, however, AGVNull vector produced less severe liver damage than Av3Null, and did not trigger the cascade of stellate cell activation into myofibroblasts and resultant hepatic fibrosis.

Sustained elevations in serum α-GST following treatment with Av3Null vector suggest that this marker may be a more sensitive indicator of hepatic damage in this mouse model than traditional serum transaminases.

NOVARTIS